

Hair loss in primary care - a guide to diagnosis, management and referral

Key points in history (usually multiple factors)

Shedding/thinning, scalp symptoms, diffuse or focal loss, facial/body hair, previous hair styling, diet, menstrual history, stress, hormonal status, medications, family history (males and females, <50) or autoimmunity

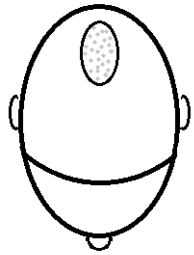
Examination and initial investigations

(1) Pattern - diffuse vs focal (2) Scarring/non-scarring - patent hair follicles (3) Inflammation - scale, pustules, erythema

Scarring/inflammation?

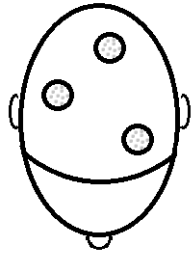
Inflammation, erythema, scale, pustules, loss of hair follicle

For scarring alopecia, review 4 weeks after initiating treatment



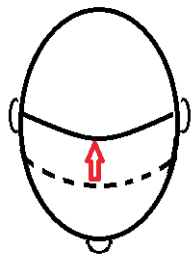
Central scarring?

CCCA (central centrifugal cicatricial alopecia)
-minimal inflammation, afrocaribbean, often element of traction
Mx: topical clobetasol (Dermovate®) 8 weeks, then oral doxycycline 100mg OD 3-6 months, stop traumatic hair styling



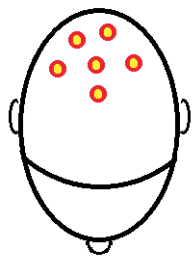
Perifollicular scale/erythema?

Lichen planus pilaris
- classic type occurs in patches
Mx: topical clobetasol 8 weeks, then oral doxycycline 100mg OD for 3-6 months



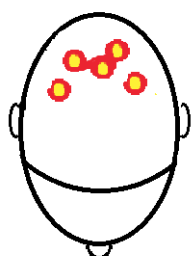
Perifollicular scale/erythema in frontal hair margin/"alice band"?

Frontal fibrosing alopecia (lichen planus variant)
-often white perimenopausal women
Mx: topical clobetasol 8 weeks, then oral doxycycline 100mg OD for 3-6 months



Pustules?

Folliculitis or folliculitis decalvans
Mx: Swab pus. Treat with hibiscrub + oral lymecycline 408mg OD or doxycycline 100mg OD for 3-6 months. Refer if severe or no response.



Abscesses/boils?

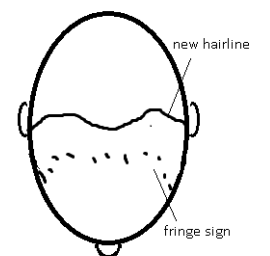
Dissecting cellulitis
Mx: Swab pus. Treat with hibiscrub + oral lymecycline 408mg OD or doxycycline 100mg OD for 3-6 months. Refer if severe or no response.

Inflammatory plaques with pigment change?

Discoid lupus.
Mx: ANA/ENA, topical clobetasol, refer

Fronto-temporal loss? Traction alopecia

- hx of extensive hair styling, see fringe sign (small hairs not involved with styling preserved)
-reversible early on, scarring when advanced
Mx: stop traction, OTC camouflage and topical 5% minoxidil (regain)



Non-scarring?

Patent hair follicles, clear scalp

Patterned hair loss?

Genetic alopecia or ♀/♂ pattern balding
- Loss on crown with preserved hair line ♀
- Loss on crown +/- receding hair line ♂
- family history (♀ penetrance less clear)
- scalp can feel irritated

Mx: OTC topical 5% minoxidil (Regain®)*, advise takes 1 year before see results, can refer ♀ for finasteride, or antiandrogen treatments such as dianette and spironolactone

Offer leaflet (From British Association Dermatologists website: www.bad.org.uk or <https://publicdocuments.sth.nhs.uk/pil1150.pdf>)
Review in 3 months

Patchy hair loss? Alopecia areata

- demarcated, circular, exclamation mark hairs
Mx: clobetasol (dermovate) trial for 8 weeks, if persists or if alopecia barbae refer.
Consider GPSI for intralesional steroids. If rapid advancement consider referring to GPSI for oral prednisolone at ½ mg/kg reducing by 10mg/week
Review in 8 weeks

Diffuse hair shedding?

Bloods: FBC, LFTs, U&Es, vitamin D, B12/folate, TFTs, haematinics, if unusual diet Zn/Mg, if hyperandrogenism hormone profile and TVUS
~Hormonal - 6 months after pregnancy, perimenopausal (may be brittle/dry), solely progesterone contraceptive
~Nutritional - aim for ferritin >70
~Stress/Depression – causes/worsens hair loss
~Medication – careful timeline
If bloods all normal or no improvement refer to diagnose diffuse alopecia areata or chronic telogen effluvium
Review in 3 months (although there may be no improvement for 6 months)

Helpful – advise on OTC camouflage, e.g. hair fibres such as nanogen, scalp tattoo, support groups, psychology

Refer to Homerton Hair Loss Clinic (C&B, fortnightly clinic)

- Inadequate response to treatment
- Scarring hair loss unless clear diagnosis
- Diagnostic uncertainty – for biopsy
- Excessive anxiety

Mx = Management

*Minoxidil (Regain®) is not prescribable on the NHS but can be bought over-the-counter or prescribed privately for women aged 18-65 years.

Authors: Dr Rowan Calloway, GP Registrar, Dr Hayley Sherratt, GP Registrar & Dr Sharon Wong, Consultant Dermatologist, Homerton Dermatology Department. Sept 2017